



Lens file: Irregular Cornea Design

The ICD (Irregular Cornea Design) lens is a 16.5mm mini-scleral contact lens, primarily used for the correction of diseased and irregular corneas

such as keratoconus/keratoglobus, corneal grafts, post-Lasik and scarring secondary to trauma or infection. ICDs are lathed from a high Dk RGP material, and are designed to be a sealed scleral design, with no tear exchange.

The lens should vault the entire cornea and limbus and land on the scleral conjunctiva, placing equal pressure around 360° of the sclera. ICD lenses are fitted using a 14-lens diagnostic fitting set, which varies in sagittal depth in 100 micron steps, for ease of fitting. The base curve of each lens is provided, but is essentially irrelevant to the fitting process as the lens does not need to align with the cornea, merely clear it.

Recent studies conducted at Pacific University College of Optometry in the US have demonstrated that the transition zone from the peripheral cornea to the limbus and onto the anterior sclera is in fact a straight line tangent, and not a concave angle (as is often assumed) (Figure 1). With this in mind, the ICD lens was designed using peripheral tangents (straight lines) rather than traditional curves. These are adjusted by modifying the angle of the tangents (steepening the angle to increase depth and flattening the angle to decrease depth).

Applications

As a scleral lens, the ICD does not come into contact with the cornea. This vaulting characteristic makes it an excellent choice for cases where a corneal RGP lens is unstable, falls out, shows poor centration, or is poorly tolerated. Corneal curvature

Continuing our series on recently introduced specialist contact lens designs, **Sophie Taylor-West** reviews the ICD mini-scleral lens for diseased and irregular corneas

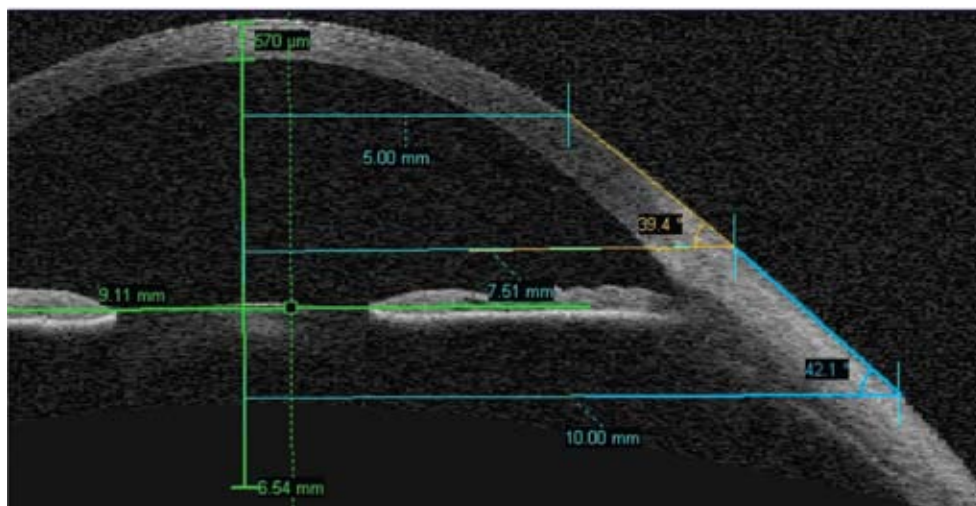


Figure 1 The corneo-scleral transition zone is a tangent rather than a concave angle

is irrelevant to the fitting process; instead the degree of corneal protuberance or sagittal height is the key consideration in arriving at the correct lens fit. Because the edges of the lens are tucked away underneath the eyelids, there is no scratchy lens edge sensation, which can cause a comfort issue for some RGP lens wearers.

Scleral lenses can also be an excellent method of managing ocular surface disease and chronic dry eye conditions such as Sjögren's syndrome and Stevens-Johnson syndrome. In such cases the retained tear reservoir trapped between lens and cornea acts to maintain corneal hydration and promote healing. The lens also provides the cornea with protection from the constant irritation caused by

the blinking eyelids. Scleral lenses are also a good choice for allergy sufferers who have a visual requirement for RGP lenses, as irritation of the tarsal conjunctiva is greatly reduced with a large-diameter lens.

Typical indications for ICD lenses are:

- Very high corneal astigmatism
- Ocular surface disease
- Post-refractive surgery cases
- Post-graft cases (including tilted and protruding-type shapes)
- Keratoconus
- Keratoglobus
- Pellucid marginal degeneration
- Corneal irregularity secondary to trauma or infection.

Technical details

ICD is a lathe cut lens, made from Paragon HDS (Dk 100) and available from No7 Contact Lenses in the UK. There are four visible curves/tangents to the lens, three of which are adjustable to optimise the lens fit: the central clearance zone (CCZ), the limbal clearance zone (LCZ) and the scleral landing zone (SLZ) (Figure 2).

The central radius of curvature varies from 8.65mm to 6.03mm, and the sagittal depths measured at the 15mm chord vary from 3,900µm (for 'normal/flatter shaped' corneas) to

TABLE 1 Technical features

Materials, manufacture and use	Design and parameters
Material: Paragon HDS (Dk 100)	Mix of spherical and aspheric base curves
Tint: Clear	Minimum centre thickness 0.3mm
Wearing schedule: Daily wear	Sag from 3,900-5,600µm (though this can be altered for optimal fit)
Replacement interval: 1-2 years	TD 16.5 (cannot be altered)
	BVP +30D to -30D in 0.25D steps
	Non-fenestrated



TABLE 2

Fitting technique

Identify the corneal condition	Based on the corneal condition, select the initial ICD trial lens with this sag	Sagittal depth @ 15mm	Diam	Power	BC mm	BC dioptre
Normal depth eyes - Normal shapes - Median flat K-reading - Ocular surface disease - Post refractive surgery	Start with the 4,200µm sag	3,900µm 4,000 4,100 4,200 4,300	16.5 16.5 16.5 16.5 16.5	+1.00 plano -1.00 -2.00 -3.00	8.65 8.04 7.18 6.89 6.49	39.00 42.00 47.00 49.00 52.00
Median depth eyes - Keratoconus - Pellucid marginal degeneration - Corneal transplants	Start with the 4,500µm sag	4,400 4,500 4,600 4,700	16.5 16.5 16.5 16.5	-4.00 -5.00 -6.00 -7.00	6.13 6.89 6.03 6.75	55.00 49.00 56.00 50.00
High depth eyes - Corneal transplants (high depth)	Start with the 4,800µm sag	4,800 4,900	16.5 16.5	-8.00 -9.00	6.49 6.37	52.00 53.00
Extreme depth eyes - Bulging corneal transplants - Kerato-globus	Select only in extreme depth cases	5,100 5,300 5,600	16.5 16.5 16.5	-11.00 -13.00 -16.00	6.14 6.03 6.03	55.00 56.00 56.00



Figure 4 Use the thickness of the lens as a gauge to estimate central clearance

Fitting procedure

The simplest way to select your initial diagnostic lens is to use the fitting chart provided with the set (Table 2). For example, if the patient has moderate keratoconus, select the 4,500µm sag lens. If the patient has a steep graft, try the 4,800µm lens. If you have a topographer or anterior OCT which allows you to calculate the sag of the eye at the 10mm chord, add 2,400µm to this figure and insert the closest trial lens from the set.

Insert the lens as described, and quickly check for bubbles (a blue torch is useful). Wait until the eye stops watering, and assess the fit with the slit lamp.

What you are aiming for is:

- Central clearance zone (CCZ): the ICD lens must completely vault the central cornea
- Limbal clearance zone (LCZ): the lens must vault the limbus around 360°
- Scleral landing zone (SLZ): the lens should land with all its weight and pressure on the sclera alone (Figure 3).

Assessing the central clearance zone

First use a white, broad beam and check for the presence of fluorescein across the whole cornea and limbus. Then switch to the blue beam with a Wratten filter to check for any areas of central touch. If you see any central touch you will need to select a new lens which is around 300-400µm deeper.

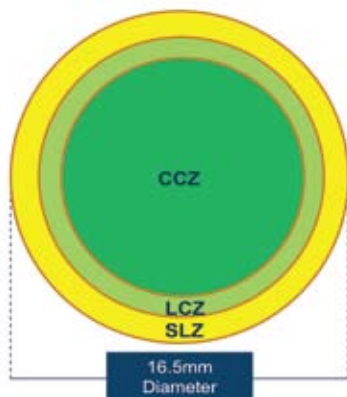


Figure 2 The lens has three adjustable visible curves/tangents

5,600µm (for extremely protuberant corneas such as very bulging grafts and keratoglobus). Toric designs are currently not available.

Handling

Proper insertion of ICD lenses is essential to success when fitting any patient. Like all non-fenestrated scleral lenses the ICD lens must be filled with saline prior to insertion. Correct technique is essential to avoid air bubbles becoming trapped under the lens. To insert, place the lens in a large DMV scleral lens inserter, or balance the lens on one, two or three fingers (like a tripod). Fill it to the brim with saline, and dip a Fluoret into the saline until it is deeply coloured. Ask your patient to bend forwards at the waist and tip their head forwards, so that their face is parallel with the floor and nose is pointing straight down.

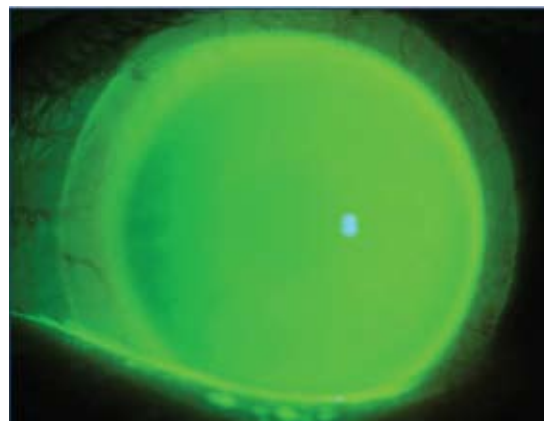


Figure 3 Ideal ICD fit showing central and limbal clearance and alignment at the sclera

Ask your patient to pull down their lower lid firmly, while you retract the top lid with one hand and place the lens gently on the cornea with the other hand. Do not push the lens on the eye too firmly, and have a tissue ready to catch the drips. Your patient should close their eye gently, then sit up and slowly open their eye. If there is a bubble trapped under the lens, however small, you must remove the lens and re-insert. A bubble is an insertion error and **not** an indication of a steep lens fit.

To remove the lens, it is easiest to use a small lens sucker. Have the patient look slightly downwards, and place the dampened sucker towards the top of the lens. Gently push the edge of the upper lid in towards the eye at the top edge of the lens, which will help release the negative pressure under the lens and release it from the eye.



Switch back to the white light and, using a thin optic section, estimate the central clearance, using the known thickness of the lens ($300\mu\text{m}$) as a gauge (Figure 4). If the clearance is around $300\mu\text{m}$, allow the lens to settle for 30-60 minutes and reassess. You can expect the lens to settle back up to $100\mu\text{m}$. The ideal fit is around $200\mu\text{m}$ of central/apical clearance after the settling period. If there is too little clearance, select a deeper lens. If the clearance is excessive, select a shallower lens.

Assessing the limbal clearance zone

Once the preferred central-fit lens has been allowed to settle, assess the limbal clearance using either a blue or white light. If you observe any limbal touch (Figure 5), order the lens with an increased LCZ angle. Each step increases the overall sag of the lens by $25\mu\text{m}$. A meaningful change is a change of five steps, which is usually sufficient to eliminate mild limbal touch (Figure 6). If you see mild superior limbal touch which disappears on down gaze, this is usually acceptable and can be ignored. The LCZ can be adjusted by up to 15 steps.

Assessing the scleral landing zone

Assess the edge of the lens using a white light. If blanching of the blood vessels is seen in any area, as seen in Figure 7 (most commonly observed in the nasal zone), or if the patient complains of discomfort under the top lid, flatten the SLZ by one step to alleviate the problem. This will also decrease the overall sag of the lens by $25\mu\text{m}$. The SLZ can be adjusted by up to three steps.

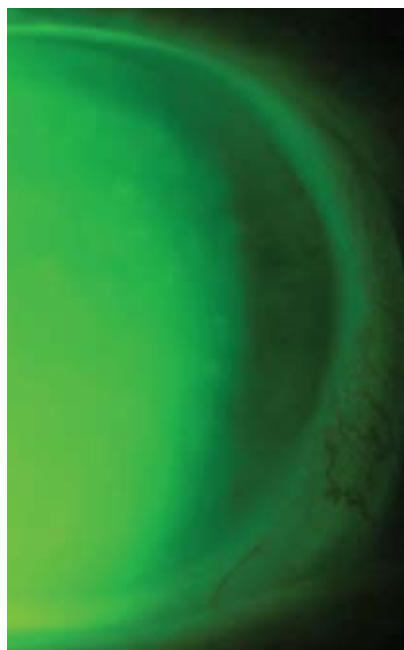


Figure 5 Limbal touch indicates a need for increased LCZ angle

Summary

Scleral lenses have long been seen by many as complex, beyond the scope of everyday practice. At just 2.5mm larger than the typical soft lens, ICD lenses are perhaps less intimidating than large diameter sclerals (to both patient and practitioner), and fitting can be attempted by any practitioner willing to take the time to help more challenging patients. They are a good option for medical contact lens cases where RGP lenses have failed, and with only three parameters to adjust, they are relatively simple to fit and manage. ●

● Optometrist **Sophie Taylor-West** practises in London in both private practice and at Moorfields Eye Hospital

FITTING TIPS

- **Always** use non-preserved saline (eg Sauflon or Lens Plus) to fill the lens, to avoid solution toxicity. Impress this upon your patients; non-compliance is a common cause of red eye reactions. In some cases you may even need non-buffered saline, such as Ami-dose
- Re-train your brain to stop thinking about base curves and concentrate on the sag/depth of the lens, as this is far more relevant when fitting sclerals
- Some mucus build up and reports of misty vision are common for the first month or so after dispensing the lens, but the eye will usually adapt and the misting will cease after a month or two. In the meantime the patient will need to periodically remove the lens, rinse and re-insert to combat this problem
- The most common cause of redness is solution toxicity. Change to another saline or solution, and if this does solve the problem, consider adjusting the edge profile
- It is quite common for the limbal curves to be slightly tight, so you may find in many cases you will need to increase the clearance here by increasing the LCZ tangent angle
- It is vital to let the lens settle for at least 30 minutes, preferably longer, before making your final assessment of the fit and over-refracting. This is due to the spongy nature of the conjunctiva, and you will often find the lens settles back by $60\text{-}100\mu\text{m}$ or more
- If your patient tells you they can feel the lens mostly at the top, under the lid, this is a strong indication that the periphery of the lens is slightly tight (even in the absence of obvious blood vessel blanching). Order the lens with a one step flatter SLZ

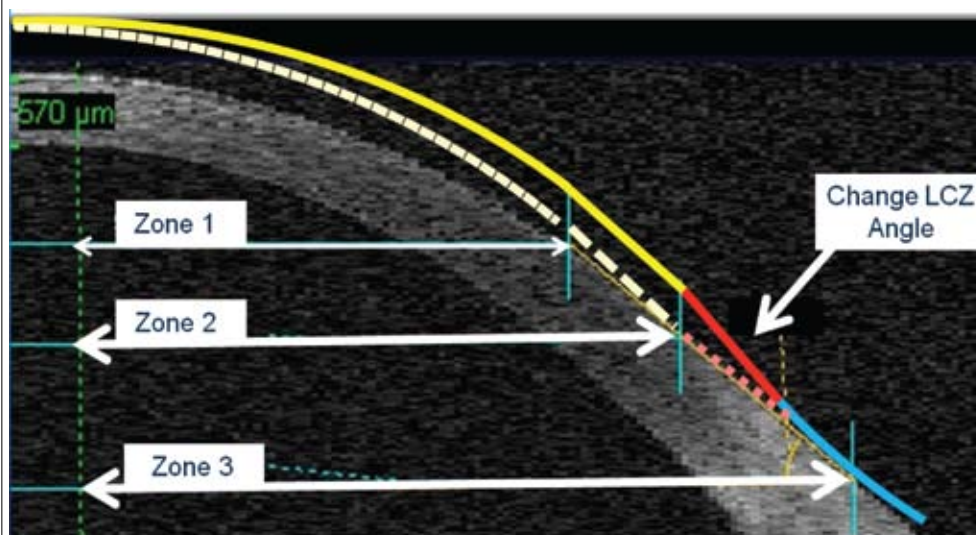


Figure 6 Increasing the LCZ angle increases the clearance at the limbus

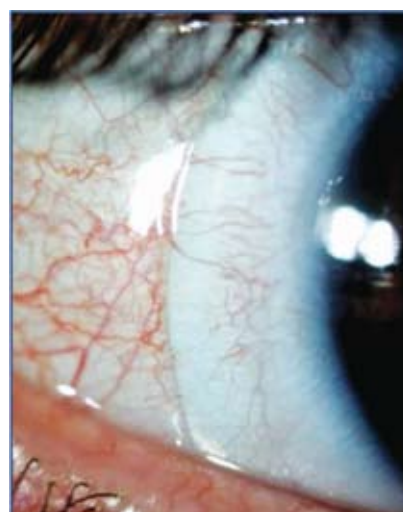

Figure 7 If blanching of vessels is present, flatten the SLZ by one step