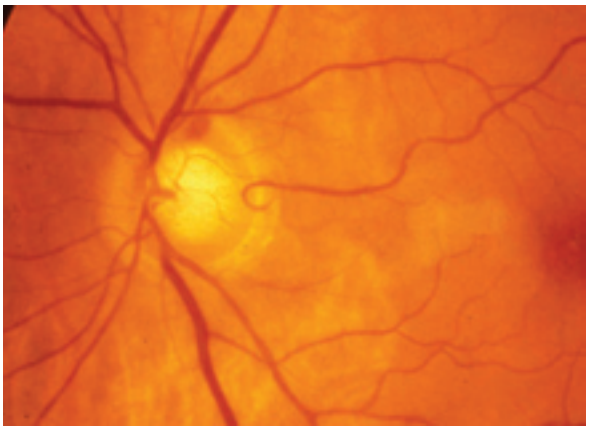

Figure 1 Primary open angle glaucoma (POAG) in an elderly man. There is thinning of the inferior temporal neuroretinal rim and a splinter or Drance haemorrhage at one o'clock

Figure 2 A 50-year-old female with POAG. There is erosion of the superior and inferior neuroretinal rims together with a superior temporal retinal nerve fibre layer (RNFL) defect

Glaucoma – Vascular and nerve fibre layer signs

Glaucomatous optic neuropathy signs

DESCRIPTION

Glaucoma is a disease of retinal ganglion cells and the associated nerve fibre layer. Since these tissues are not easy to visualise, clinicians usually detect glaucoma from characteristic changes in the optic nerve head or the visual field or both. Characteristic optic nerve head changes include loss of symmetry in the neuroretinal rim (NRR), or in the comparison between NRR of the two eyes, or in detecting change over time (see Glaucoma – Neuro-retinal rim assessment). Associated changes in the vasculature or retinal nerve fibre layer can assist the clinician in detecting glaucoma.

SIGNS

● **Drance haemorrhage:** Flame-shaped and splinter hemorrhages at the optic disc margin represent a significant and relatively specific risk factor for glaucoma (Early manifest glaucoma trial). They seem to have a particular association with normal tension glaucoma. Drance haemorrhages occur in about 10 per cent of glaucoma cases. They are typically an isolated finding, unlike the haemorrhages associated with conditions such as diabetic retinopathy, retinal vein occlusion or hypertension.

● **Bayoneting of blood vessels:** If blood vessels bend or kink sharply when they pass over the edge of the cup, then this condition is known as bayoneting (Image: see Glaucoma – Neuro-retinal rim assessment). Bayoneting may be a sign of erosion or loss of the NRR.

● **Baring and bridging of blood vessels:** These signs arise when there is erosion of the NRR leaving the blood vessels distant from the neural tissue. Some patients have blood vessels that track along the inner margin of the NRR, with glaucoma these arc-shape vessels may be left bare or isolated from the margin of the cup. Bridging (overpassing) refers to vessels that hang in space over an area of lost neural tissue.

● **Pallor of the NRR:** The healthy NRR rim is usually an orange-red hue due to the vascular perfusion of the tissue. Pallor occurs when the natural colour of the NRR is lost, leaving a yellow, grey or white colour. Advanced glaucoma is associated with pallor of the NRR, but it may also occur in other optic neuropathies, such as chiasmal compression or anterior ischaemic optic neuropathy. 'Pallor-cup discrepancy' refers to the phenomenon where the cupping has advanced more than the pallor, suggesting the condition may be glaucoma. Apparent colour of the disc is also influenced by a number of factors, including the presence of cataract.

● **Retinal nerve fibre layer (RNFL) defects:** In the normal eye, the main nerve fibre bundles are often easily appreciated, particularly in the young patient, with striated light reflections running superiorly and inferiorly from the disc and then curving temporally. A diffuse loss of the RNFL may not be easy to appreciate, but may be best visualised with a red-free filter or quantified with scanning-laser ophthalmoscope methods. A localised RNFL defect appears as a dark wedge shape, pointing at the optic disc, and is a relatively specific sign of glaucoma.

Pupil dilatation and the utilisation of binocular stereoscopic examination techniques are essential.

PREVALENCE, DIFFERENTIAL DIAGNOSIS, MANAGEMENT

See the individual glaucoma conditions listed in: Glaucoma classification. ●

The full series of these articles will be available in the book *Posterior Eye Disease and Glaucoma A-Z* by Bruce AS, O'Day J, McKay D and Swann P. £39.99. For further information click on the Bookstore at **opticianonline.net**

● **Adrian Bruce** is a Chief Optometrist at the Victorian College of Optometry and a Senior Fellow, Department of Optometry and Vision Sciences, The University of Melbourne.
● **Justin O'Day** is an Associate Professor in the Department of Ophthalmology, The University of Melbourne and Head Of Neuro-Ophthalmology Clinic, Royal Victorian Eye and Ear Hospital.
● **Daniel McKay** is a Medical Officer at the Royal Victorian Eye & Ear Hospital.
● **Peter Swann** is Associate Professor in the School of Optometry, Queensland University of Technology.